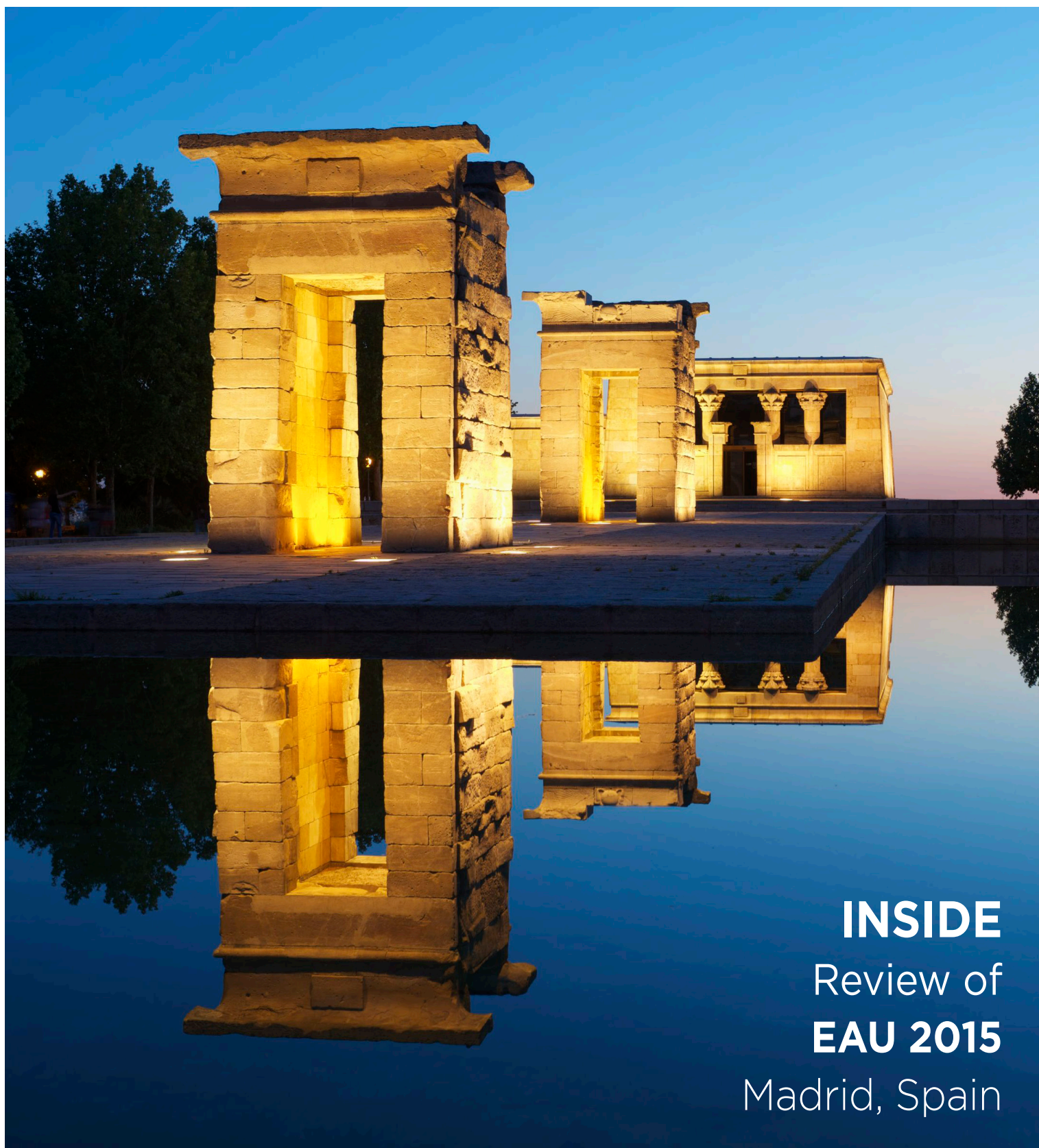


EMJ EUROPEAN
MEDICAL JOURNAL

UROLOGY

ISSN 2053-4213

Vol 3.2 • May 2015 • emjreviews.com



INSIDE

Review of

EAU 2015

Madrid, Spain

HOLMIUM LASER ENUCLEATION OF THE PROSTATE (HoLEP): OUR EXPERIENCE WITH THE LEARNING CURVE AND THE DEVELOPMENT OF THE 'EN-BLOC NO-TOUCH' TECHNIQUE

*Cesare Marco Scoffone, Cecilia Maria Cracco

Department of Urology, Cottolengo Hospital of Torino, Torino, Italy

**Correspondence to scoof@libero.it*

Disclosure: C.M. Scoffone is a consultant for Boston Scientific, Cook Medical, Lumenis, Porgès Coloplast, and Karl Storz. C.M. Cracco has received honoraria from Boston Scientific, Porgès Coloplast, and Takeda. Both authors received a research grant from Astellas.

Received: 19.02.15 **Accepted:** 03.03.15

Citation: EMJ Urol. 2015;3[2]:111-116.

ABSTRACT

Background: Holmium laser enucleation of the prostate (HoLEP) is a safe and effective therapeutic option in patients suffering from benign prostatic hyperplasia (BPH) of any size. In spite of its excellent and durable outcomes, HoLEP is gaining widespread acceptance very slowly, since it is perceived as requiring significant endoscopic skill and having a steep learning curve. Here we present our 4-year experience with this technique after more than 200 cases, describing our learning curve with the traditional three-lobe technique of Gilling, and its progressive modification into the so-called 'en-bloc no-touch' technique.

Methods: From January 2011 to December 2014, 200 consecutive patients diagnosed with symptomatic and obstructive BPH underwent HoLEP in our department. Demographic and clinical data were prospectively collected. Age, total operating time, enucleation time and efficiency, morcellation time, energy employed, adenoma weight, hospital stay, and complications were recorded.

Results: The HoLEP learning curve in our department included an initial 1-year experience with the traditional technique of Gilling, and its progressive modification with the development of the so-called 'en-bloc no-touch' approach, subsequently standardised step by step. At the beginning of the learning curve short time intervals between the procedures are relevant for faster learning. With time and experience, adenomas of all sizes are treated, with significantly shorter total operating and enucleation times, significantly increased enucleation efficiency, decreased use of energy (meaning fewer postoperative voiding symptoms), and fewer complications. Morcellation time is more device-dependent than surgeon-dependent, and is also influenced by the composition of the adenomatous tissue.

Conclusion: The 'en-bloc no-touch' technique seems to simplify the procedure, making it easier to teach and to learn. HoLEP safety and efficacy are improved by increasing experience, as expected, but apparently also by the application of our modified and standardised procedure.

Keywords: Prostatic hyperplasia, holmium laser enucleation of the prostate (HoLEP), lasers.

INTRODUCTION

Holmium laser enucleation of the prostate (HoLEP) - introduced in 1998 by Peter Gilling et al.¹ - is an endoscopic procedure mimicking open prostatectomy and allowing complete anatomic removal of the prostatic adenoma. Over the past decade HoLEP has been proven to be a well-

tolerated and effective therapeutic option²⁻⁴ in patients suffering from benign prostatic hyperplasia (BPH) of any size.^{5,6} Therefore HoLEP currently represents a valid alternative to both transurethral resection of the prostate (considered the reference standard treatment for small, <30-40 ml, and medium-sized, 40-80 ml, prostates),^{2,4-6} and open prostatectomy (still taken into account

for larger prostates, >80-100 ml, by most guidelines).^{7,8} HoLEP obviates the complications of open surgery and using saline as an irrigant avoids the risk of transurethral resection syndrome, increased in cases of large prostates, which are technically more difficult to resect safely and quickly. Thus, HoLEP is also cost-effective.⁹

In spite of its excellent and durable outcomes, HoLEP has proved to be slow in gaining widespread acceptance, since it is perceived as requiring significant endoscopic skill and having a steep learning curve (30-50 cases).^{10,11} Furthermore, there is an additional learning curve during transition from medium-sized to both smaller and larger prostates.¹²⁻¹⁴ Consequently, some urologists prefer more invasive and expensive options, such as laparoscopic^{15,16} or robotic^{16,17} simple prostatectomy. For these reasons, modular training HoLEP programmes are now available to enable safe and efficient learning of this technique.¹⁸ Despite this, being considered technically difficult to perform, HoLEP is still limited to expert teams at high volume centres in Italy. We started performing HoLEP at our department in January 2011 and here we present our 4-year experience with this technique after more than 200 cases, describing our learning curve with the traditional three-lobe technique of Gilling¹⁹ and its progressive modification into the so-called 'en-bloc no-touch' technique.

METHODS

From January 2011 to December 2014, 200 consecutive patients (none on anticoagulant or antiplatelet medication) diagnosed with symptomatic and obstructive BPH underwent HoLEP in our department, performed by a single surgeon (C.M.S.) with associated fellows. A continuous flow 26 Fr Storz resectoscope equipped with 12° optics and a 550-µm end-firing laser fibre were employed. The 100W Versapulse holmium laser (Lumenis) was used (2 J/50 Hz). In three cases we used the 120W Versapulse holmium laser (Lumenis) (2 J/30 Hz/medium-long pulse duration). Morcellation was performed using a 24 Fr rigid nephroscope (Storz) and the Versacut mechanical morcellator (Lumenis). Demographic and clinical data were prospectively collected. Age, total operating time, enucleation time and efficiency, morcellation time, energy employed, adenoma weight, hospital stay, and complications were recorded.

OUR INITIAL LEARNING CURVE APPLYING THE TRADITIONAL THREE-LOBE TECHNIQUE

We started performing HoLEP autonomously in January 2011, after some tutoring with experts. The data relative to our first 19 procedures, performed according to the traditional three-lobe technique, are shown in [Tables 1](#) and [2](#). There was one long-term stress urinary incontinence, no transient stress urinary incontinences (only urgent micturitions), two intraoperative bleedings requiring additional haemostasis with the bipolar resectoscope (10%), and one (5%) recatheterisation the night after catheter removal (and subsequent successful removal). During this first part of the learning curve we thoroughly analysed the steps that we considered critical and difficult to perform:

- 1) Finding the correct plane between prostatic capsule and adenoma three times during the procedure, at 5, 7, and 12 o'clock, with the risk of enucleating in an incorrect plane within the adenoma, to perforate the capsule and/or to undermine the bladder neck at the beginning of the procedure.
- 2) Performing an adequate 12 o'clock incision, avoiding significant bleeding if too deep or a too-distal descent towards the sphincter.
- 3) Affording the rotation of the lateral lobes around the axis of their residual attachment to the bladder neck, while progressing with their enucleation, without losing the correct orientation.
- 4) Obtaining a clear vision of the mucosal strip from 10 to 2 o'clock, for its safe incision maximally preserving the external sphincter.

DEVELOPMENT OF THE 'EN-BLOC NO-TOUCH' TECHNIQUE

Trying to find a solution to our difficulties, time after time we introduced alterations in the traditional three-lobe technique of Gilling, progressively developing the so-called 'en-bloc no-touch' technique, which we applied in our daily routine in more than 200 BPH patients. Other authors in the past had already introduced modifications of the traditional technique in order to simplify it.^{14,20}

Table 1: Data relative to patients undergoing HoLEP in 2011.

Year	Age range, years	Number of procedures	Procedures per month	Mean adenoma weight \pm SD, g
2011	61-88	19	1-2	43.5 \pm 33.5

HoLEP: holmium laser enucleation of the prostate; SD: standard deviation.

Table 2: Data relative to HoLEP procedures in 2011.

Year	Total operating time \pm SD, min	Enucleation time \pm SD, min	Enucleation efficiency, g/min	Energy employed \pm SD, kJ	Morcellation time \pm SD, min
2011	88.0 \pm 35.4	60 \pm 28	0.7	156 \pm 69	14 \pm 11

SD: standard deviation; HoLEP: holmium laser enucleation of the prostate.

Why 'En-Bloc'

Adenoma enucleation begins at the apex lateral to the verumontanum, usually on the left side. The cleavage plane between adenoma and capsule is prominent at this site and particularly easy to identify. This incision between left and median lobe can be retrogradely deepened and widened towards the bladder neck, but this step is optional (partially 'en-bloc' approach, most frequently applied, obtaining a final horseshoe-like adenoma). Otherwise, the dissection is carried out without separating the median and the lateral lobes, with an intact prostatic urethra (complete 'en-bloc' approach). In both cases the correct plane has to be identified only once instead of three times, reducing the risk of error.

The left lobe is then isolated from the apex towards the bladder neck in a side-to-side manner, ascending cranially from 5 to 3 o'clock (**Figure 1**). Its detachment is completed from 3 to 12 o'clock and goes on towards the right side from 12 to 9 o'clock. Going back to the initial left apical incision - when performed - the mucosa is horizontally incised above the verumontanum, reaching the apex of the right lobe; the median lobe is then isolated, reaching the bladder neck, and remains attached to the right lobe. Enucleation of the right lobe goes on as described for the left lobe, from 7 to 9 o'clock, circumferentially joining its already detached superior part from 9 to 12 o'clock. The enucleated 'en-bloc' adenoma is now fixed from 10 to 2 o'clock only by a residual urothelial strip (while behind it the adenoma is almost completely detached) (**Figure 2**), which has to be incised

before pushing the adenoma within the bladder under direct vision, limiting the risk of potential sphincteric damage. This progressive 'en-bloc' enucleation of the adenoma kept in place until the very last steps of enucleation by the anterior mucosa avoids its bothersome mobility. Two oblique incisions are finally made on the residual mucosa of the lateral lobes, and a final horizontal incision is performed on the residual mucosal strip at 12 o'clock, as proximal as possible to the bladder neck. Now the completely enucleated adenoma can be pushed inside the bladder lumen for morcellation.

Why 'No-Touch'

The mucosa at the apex lateral to the verumontanum is initially incised, but afterwards the capsular plane is mainly developed using blunt dissection. The adenoma is detached lifting it with the beak of the endoscope, serving as the surgeon's finger during open simple prostatectomy, and progressively uncovering the correct capsular plane under vision (**Figure 1**). The laser energy is mainly employed to release the connective shoots put in tension by pushing the adenoma away from the capsule. Vision is optimal, blood vessels can be easily identified in advance (**Figure 3**) and can undergo targeted haemostasis, defocusing the laser to 2-3mm. The laser fibre is activated at a short distance from the tissue, most commonly dissolving rather than incising it. This effect is particularly evident using the 120W device, reducing laser frequency and employing the medium-long pulse length. In this way, small adenomas and areas of strongly adhering capsule may be afforded

without capsular perforation. Both the use of mechanical detachment and the 'no-touch' approach allow less energy supply to the capsular plane, implying fewer postoperative voiding symptoms.

Clinical Outcomes

From 2012 HoLEP was always performed according to the described 'en-bloc no-touch' technique, standardised step by step. The hospital stay ranged

from 2 to 3.5 days for all patients, the first day being the day of surgery, the second postoperative day being the day of irrigation removal as well as catheter removal when possible a couple of hours afterwards, and the third postoperative day being the alternative day of catheter removal early in the morning. Since our hospital does not have an emergency department the current policy is to monitor spontaneous voiding for 24 hours after catheter removal, before sending the patient home.

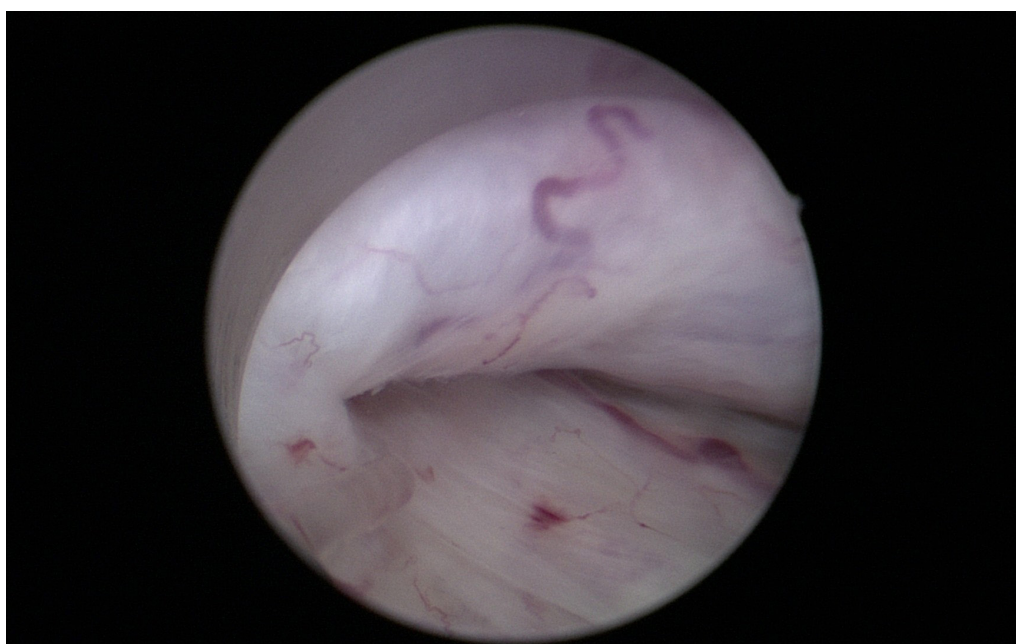


Figure 1: 'No-touch' enucleation of a prostatic adenoma, clear identification of the correct plane between left lobe and capsule.

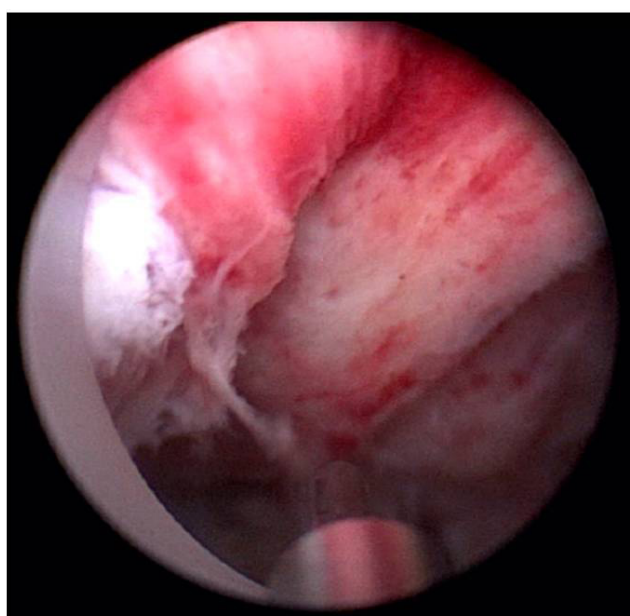


Figure 2: The final mucosal strip from 10 to 2 o'clock.

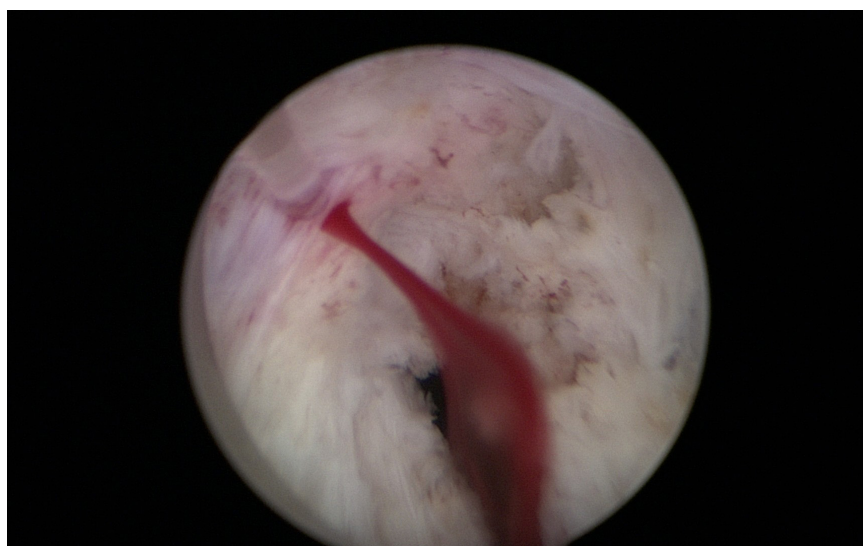

Figure 3: Targeted haemostasis of a capsular artery by defocusing the laser fibre.

Table 3: Data relative to patients undergoing 'en-bloc no-touch' HoLEP from 2012 to 2014.

Year	Age range, years	Number of procedures	Procedures per month	Mean adenoma weight \pm SD, g
2012	54-83	34	3	42.1 \pm 25
2013	53-87	79	>7	52.1 \pm 41
2014	51-85	60	>7	57.7 \pm 40

SD: standard deviation; HoLEP: holmium laser enucleation of the prostate.

Table 4: Data relative to 'en-bloc no-touch' HoLEP procedures from 2012 to 2014.

Year	Total operating time \pm SD, min	Enucleation time \pm SD, min	Enucleation Efficiency, g/min	Energy employed \pm SD, kJ	Morcellation time \pm SD, min
2012	65.6 \pm 20	39.8 \pm 17	1.00	91.7 \pm 28	7.6 \pm 4.3
2013	59.9 \pm 28	30.3 \pm 13	1.72	82.0 \pm 28.8	10.9 \pm 13.5
2014	58.8 \pm 25	32.0 \pm 15	1.8	85.0 \pm 31	9.0 \pm 7.4

SD: standard deviation; HoLEP: holmium laser enucleation of the prostate.

As shown in [Table 3](#) and [Table 4](#), HoLEP efficiency was globally increased, performing the procedure more frequently in 2013 and 2014 than in 2011 and 2012 (from 1-3 to >7 times a month). Year after year prostatic adenomas of increasing volumes were removed with shorter total operating times, employing less time for the enucleation and less energy as well. The small increase in the morcellation time (which is more device-dependent than surgeon-dependent) is related to the corresponding increase in adenoma weight removed. In 2012 there were three patients (8.8%)

requiring postoperative endoscopic haemostasis, in 2013 two (2.5%), and in 2014 one (1.7%). There were neither long-term nor transient stress urinary incontinences (only urgent micturitions during the first 10-15 days after catheter removal). Overall, seven patients (4%) required recatheterisation, followed by successful catheter removal.

CONCLUSION

The HoLEP learning curve in our department included an initial 1-year experience with the

traditional technique of Gilling, and its progressive modification with the development of the so-called 'en-bloc no-touch' approach, subsequently standardised step by step. At the beginning of the learning curve, short time intervals between the procedures are relevant for faster learning. With time and experience, adenomas of all sizes can be treated, with significantly shorter total operating and enucleation times, significantly increased enucleation efficiency, decreased use of energy (meaning fewer postoperative voiding symptoms),

and fewer complications. Morcellation time is more device-dependent than surgeon-dependent, and is also influenced by the composition of the adenomatous tissue.¹⁹ The 'en-bloc no-touch' technique appears to simplify the procedure, making it easier to teach and to learn. HoLEP safety and efficacy are improved by increasing experience as expected, but apparently also by the application of our modified and standardised procedure.

REFERENCES

1. Gilling PJ et al. Holmium laser enucleation of the prostate (HoLEP) combined with transurethral tissue morcellation: an update on the early clinical experience. *J Endourol.* 1998;12(5):457-9.
2. Montorsi F et al. Holmium laser enucleation versus transurethral resection of the prostate: results from a 2-center, prospective, randomized trial in patients with obstructive benign prostatic hyperplasia. *J Urol.* 2004;172(5 Pt 1):1926-9.
3. Ahyai SA et al. Meta-analysis of functional outcomes and complications following transurethral procedures for lower urinary tract symptoms resulting from benign prostatic enlargement. *Eur Urol.* 2010;58(3):384-97.
4. Yin L et al. Holmium laser enucleation of the prostate versus transurethral resection of the prostate: a systematic review and meta-analysis of randomized controlled trials. *J Endourol.* 2013;27(5):604-11.
5. Lee MH et al. Holmium laser enucleation of the prostate is effective in the treatment of symptomatic benign prostatic hyperplasia of any size including a small prostate. *Korean J Urol.* 2014;55(11):737-41.
6. Herrmann TR et al. EAU guidelines on laser technologies. *Eur Urol.* 2012;61(4):783-95.
7. Naspro R et al. Holmium laser enucleation of the prostate versus open prostatectomy for prostates >70 g: 24-month follow-up. *Eur Urol.* 2006;50(3):563-8.
8. Gilling PJ et al. Holmium laser enucleation of the prostate for glands larger than 100 g: an endourologic alternative to open prostatectomy. *J Endourol.* 2000;14(6):529-31.
9. Salonia A et al. Holmium laser enucleation versus open prostatectomy for benign prostatic hyperplasia: an inpatient cost analysis. *Urology.* 2006;68(2):302-6.
10. El-Hakim A, Elhilali MM. Holmium laser enucleation of the prostate can be taught: the first learning experience. *BJU Int.* 2002;90(9):863-9.
11. Bae J et al. The learning curve for holmium laser enucleation of the prostate: a single-center experience. *Korean J Urol.* 2010;51(10):688-93.
12. Shah HN et al. Prospective evaluation of the learning curve for holmium laser enucleation of the prostate. *J Urol.* 2007;177(4):1468-74.
13. Placer J et al. Holmium laser enucleation of prostate: outcome and complications of self-taught learning curve. *Urology.* 2009;73(5):1042-8.
14. Dusing MW et al. Holmium laser enucleation of the prostate: efficiency gained by experience and operative technique. *J Urol.* 2010;184(2):635-40.
15. Porpiglia F et al. Transcapsular adenomectomy (Millin): a comparative study, extraperitoneal laparoscopy versus open surgery. *Eur Urol.* 2006;49(1):120-6.
16. Autorino R et al. Perioperative outcomes of robotic and laparoscopic simple prostatectomy: a European-American multi-institutional analysis. *Eur Urol.* 2014;doi:10.1016/j.eururo.2014.11.044. [Epub ahead of print].
17. Sotelo R et al. Robotic simple prostatectomy. *J Urol.* 2008;179(2):513-5.
18. Aho T, Herrmann TR. Description of a modular mentorship programme for holmium laser enucleation of the prostate. *World J Urol.* 2014;doi:10.1007/s00345-014-1407-1. [Epub ahead of print].
19. Hussein MIY et al. Holmium laser enucleation of the prostate, tips and tricks not just for beginners. *Videourology* 2014;doi:10.1089/vid.2014.0040. [Epub ahead of print].
20. Gong YG et al. Holmium laser enucleation of the prostate: a modified enucleation technique and initial results. *J Urol.* 2012;187(4):1336-40.